

## ORIGINAL REPORT

# Safety and accuracy of blind vs. ultrasound-guided dorsal retrobulbar nerve blocks in horses—A cadaveric study

Katharina Thieme<sup>1,2</sup>  | Luis Mesquita<sup>3</sup> | Simona Lieberth<sup>2</sup> | Christian Dancker<sup>1</sup> | Marcus Georg Doherr<sup>4</sup> | Johanna Corinna Eule<sup>1</sup>

<sup>1</sup>Small Animal Clinic, Freie Universität Berlin, Berlin, Germany

<sup>2</sup>Equine Clinic, Surgery and Radiology, Freie Universität Berlin, Berlin, Germany

<sup>3</sup>Radiology Department, Willows Veterinary Centre and Referral Service, Solihull, UK

<sup>4</sup>Institute for Veterinary Epidemiology and Biostatistics, Freie Universität Berlin, Berlin, Germany

## Correspondence

Katharina Thieme, Small Animal Clinic, Freie Universität Berlin, Oertzenweg 19b, Berlin 14163, Germany.

Email: [katharina.thieme@fu-berlin.de](mailto:katharina.thieme@fu-berlin.de)

## Funding information

European College of Veterinary Ophthalmologists

## Abstract

**Objective:** There is limited knowledge regarding the safety and accuracy of ultrasound-guided retrobulbar nerve blocks in horses. The aim of this study was to compare these parameters between blind and ultrasound-guided injection techniques for the dorsal retrobulbar nerve block in horses.

**Methods:** Equine cadaver heads were used to inject the retrobulbar space with contrast medium (CM). Injections were performed either blindly based on anatomic landmarks (blind group,  $n = 44$ ) or under ultrasonographic guidance (US-group,  $n = 44$ ), equally divided between an experienced and unexperienced operator. Needle position and distribution of CM were assessed with computed tomography imaging and evaluated by a board-certified veterinary diagnostic imager blinded to the technique. Safety and accuracy of both techniques were compared.

**Results:** Ocular penetration was observed in two cases ( $n = 2/44$ ) in the blind group but not in the US group ( $n = 0/44$ ). No intrathecal, intraneural, or intravascular injections were seen in either group. Safety was significantly improved in the US group ( $p = .026$ ). There was no statistically significant difference between the groups regarding the accuracy of the injection. Excellent accuracy was achieved more often with the ultrasound-guided technique ( $n = 11/22$ ) than with the blind technique ( $n = 7/22$ ) when performed by the unexperienced operator, but this difference was not statistically significant.

**Conclusion:** To prevent globe-threatening complications and improve the safety of the injection, we recommend using the ultrasound-guided injection technique for the dorsal retrobulbar nerve block.

## KEYWORDS

anesthesia, equine, local, ophthalmic, regional, standing surgery

This is an open access article under the terms of the [Creative Commons Attribution-NonCommercial-NoDerivs](https://creativecommons.org/licenses/by-nc-nd/4.0/) License, which permits use and distribution in any medium, provided the original work is properly cited, the use is non-commercial and no modifications or adaptations are made.

© 2022 The Authors. *Veterinary Ophthalmology* published by Wiley Periodicals LLC on behalf of American College of Veterinary Ophthalmologists.

## 1 | INTRODUCTION

Regional anesthesia is widely used to provide intra- and postoperative analgesia and is the only pharmacological approach that is proven to completely block the transmission of pain signals.<sup>1</sup> Regional anesthesia for surgical procedures prevents the increase of stress-related biomarkers, promotes better recovery quality, and decreases postoperative pain scores in dogs.<sup>2</sup> The eye and orbit are extensively innervated structures; therefore, regional anesthesia is recommended in all animals undergoing ophthalmic surgery.<sup>3</sup>

Retrobulbar anesthesia has the potential of anesthetizing several nerves of the retrobulbar space simultaneously. Besides a sensory and motor blockage, centralization of the eye can be achieved, obviating the need for a neuromuscular blockade and facilitating diagnostic procedures and surgeries. As a part of a multimodal approach to analgesia, regional anesthesia can improve the patient's comfort and help to avoid deep planes of anesthesia and its associated complications. Additionally, the administration of other analgesic and sedative drugs such as opioids can be reduced also aiming at minimizing their potential side effects. The increasing popularity of surgeries in the standing, sedated horse combined with the beneficial effects of regional anesthesia make it possible to avoid general anesthesia completely in many cases.<sup>4</sup> Furthermore, a heart rate decrease associated with the initiation of the oculocardiac reflex can be prevented with a retrobulbar nerve block.<sup>5</sup>

Potential complications associated with retrobulbar anesthesia are orbital hemorrhage, chemosis, and direct damage to the optic nerve or globe.<sup>6,7</sup> Intravascular or intrathecal injection could cause brainstem anesthesia, seizures, or cardiac arrest.<sup>8,9</sup>

Ultrasound-guided (US-guided) peripheral nerve blocks are well established in human medicine and US guidance is gaining popularity in ophthalmic regional anesthesia in human medicine.<sup>10</sup> US guidance is a non-invasive tool that improves the quality and duration of peripheral-nerve blockade<sup>11</sup> and reduces the incidence of complications.<sup>12</sup> The technique further results in a quicker onset of the block in peripheral nerve blockade in humans.<sup>11</sup>

Wagatsuma et al.<sup>13</sup> compared peribulbar regional anesthesia in dogs with and without US guidance. Safety appeared to be increased with the US-guided technique, resulting in lower intraocular pressure after the injection and less subconjunctival hemorrhage when compared to blindly injected orbits. US-guided retro- and peribulbar injections in horses<sup>14–16</sup> and rabbits<sup>17</sup> showed very good visualization of the needle and anatomic landmarks in the majority of cases. When ultrasonographic visualization

was impaired, injections were less successful. In a recent study, the blind and US-guided retrobulbar nerve blocks in horses were compared and the training effect was investigated.<sup>16</sup> The results of this study show a trend toward improved needle position and a positive training effect with US guidance.

The purpose of this study was to compare the safety and accuracy between the blind and US-guided injection technique for the dorsal retrobulbar nerve block (DRNB) in horses. In addition, the influence of the experience level of the operator on the outcome of the injection was investigated.

## 2 | MATERIALS AND METHODS

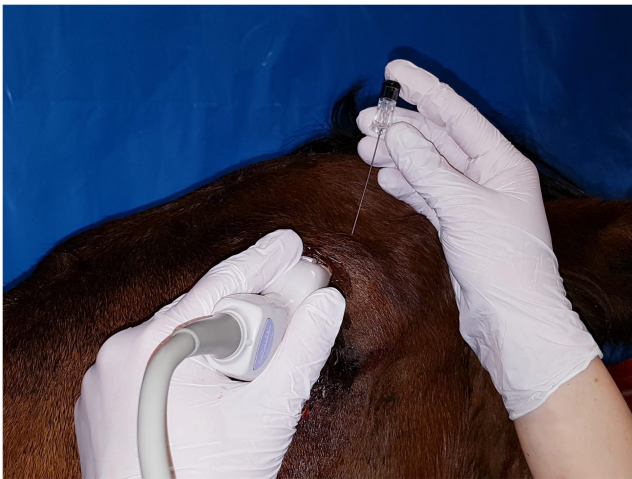### 2.1 | Animals

Forty-four horses of different breeds without obvious signs of ocular and orbital disease were used. The horses were euthanized due to reasons unrelated to this study or killed by bolt shot and exsanguination for food production. Heads were removed from the trunk within 24 h after death and cooled for a maximum of 48 h. Cadaver heads were allowed to warm up to room temperature (approx. 20–25°C) for 3–4 h before being used in this study. Intraocular pressure was assessed using a rebound tonometer (Tonovet®, iCare, Tiolat) and restored as required. Uniform intraocular pressure was achieved by injection of saline solution into the eyeball using a 22 G needle in the region of the dorsolateral sclera, 10 mm behind the limbus, until a pressure between 20 and 30 mmHg was reached. The orbits for the blind ( $n = 44$ ) and US-guided ( $n = 44$ ) dorsal retrobulbar injections were randomly assigned ([randomizer.com](https://randomizer.com)) and equally divided between two operators. Retrobulbar injections were performed by either an experienced operator (CE, DECVO) or an unexperienced operator (SL, final year veterinary medicine student).

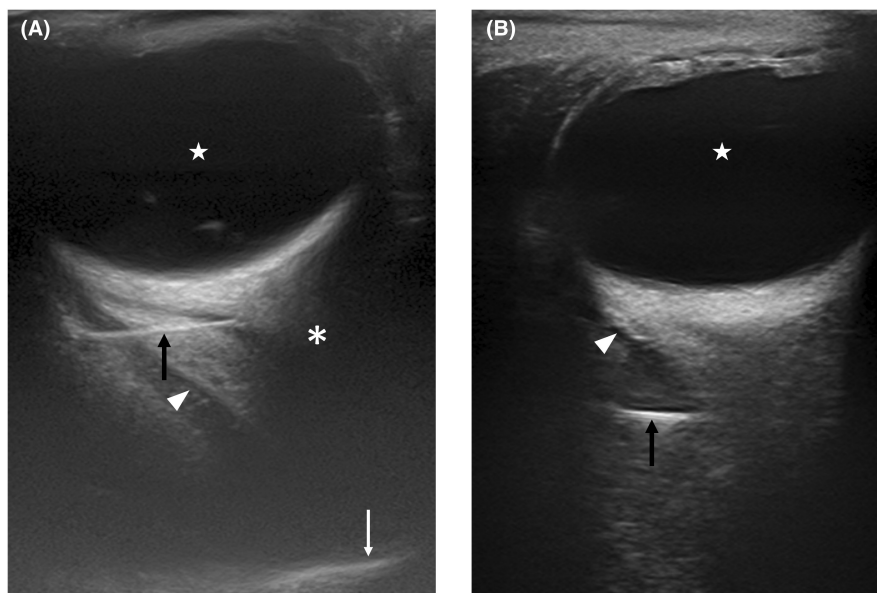
The blind injection was performed as previously described.<sup>18</sup> Briefly, a 22 G, 75 mm spinal needle (B. Braun) was placed through the skin, perpendicular to the skull in the orbital fossa just posterior to the posterior aspect of the dorsal orbital rim. The needle was advanced until the eye showed a slight dorsal movement and further until the eye moved back to its normal position.

The US-guided technique was performed using a technique similar to that described by Morath et al.<sup>14</sup> Ultrasonographic visualization was performed through the closed upper eyelid (Toshiba Aplio 500 ultrasonography unit with a 10 MHz linear ultrasound transducer, Toshiba Medical Systems Corporation) with the linear transducer placed in plane with the needle (Figure 1).

After visualization of the optic nerve a 22 G, 75 mm spinal needle (B. Braun) was inserted at the rostral aspect of the supraorbital fossa, caudomedially to the posterior aspect of the zygomatic process, in a slightly craniomedial direction. The needle was then advanced under ultrasonographic visualization, with the aim to place the needle tip just behind the eyeball in the craniocentral part of the cone formed by the retractor bulbi muscle. Ultrasound visualization was scored as described by Morath et al.<sup>14</sup> (Figure 2, Table 1).



**FIGURE 1** Image showing the ultrasound-guided technique for the dorsal retrobulbar nerve block in horses. Image acquisition is achieved through the closed upper eyelid, with the linear ultrasound transducer placed in plane with the needle.



**FIGURE 2** Ultrasound images generated during the performance of the dorsal retrobulbar nerve block in a horse cadaver using the ultrasound-guided injection technique. (A) shows excellent ultrasound visualization, where the eyeball (star), retrobulbar muscle cone with intraconal space (arrowhead), optic nerve (asterisk) and bony shadow of the orbit (white arrow), and the needle (black arrow) are all visualized, and the needle can be visualized in the same ultrasound image as the optic nerve. (b) shows poor ultrasound visualization, because the previously mentioned structures were not all clearly visualized.

## 2.2 | Computed tomography

After placement of the needle its position was assessed via computed tomography (CT) imaging (32 slices CT scanner Aquilon TSX-201A; Canon Medical Systems Corporation). Without repositioning the needle, 12 ml of contrast medium (CM) (Accupaque™ 300 mg; GE Healthcare Buchler GmbH) was injected. For this purpose, an extension tube was attached to the spinal needles to decrease the risk of needle movement while attaching the syringe to the cannula and during the injection of the CM. The CM was kept at 37°C until injection to decrease its viscosity. Immediately after injection, a second CT scan was performed to assess the distribution of the contrast agent.

Computed tomography images were evaluated by a board-certified veterinary diagnostic imager (LM, DECVDI) blinded to the injection technique and operator. The CT findings were described similarly to the scheme presented by Morath et al.<sup>14</sup> and Shilo-Benjamini et al.<sup>19</sup> and the injections scored regarding their accuracy and safety (Table 2).

## 2.3 | Statistical analysis

The statistical analysis was performed using a commercially available software program (SPSS, Version 28.0; SPSS Inc.). Numerical data of CT measurements were tested for normality using the Shapiro–Wilk test.

Visualization	
Poor	<ul style="list-style-type: none"> <li>The eyeball, retrobulbar muscle cone with intraconal space, optic nerve and bony shadow of the orbit, and the needle were not all clearly visualized</li> </ul>
Good	<ul style="list-style-type: none"> <li>All the previously mentioned structures and the needle were visualized, but the needle could not be placed in the same ultrasound image as the optic nerve</li> </ul>
Excellent	<ul style="list-style-type: none"> <li>All previously mentioned structures and the needle could be visualized, and the needle was visualized in the same ultrasound image as the optic nerve</li> </ul>
Spread	
Unsatisfactory	<ul style="list-style-type: none"> <li>Greater than 50% cranial spread of the injectate</li> </ul>
Satisfactory	<ul style="list-style-type: none"> <li>Both cranial and caudal spread of the CM was observed, with &gt;50% of the injectate spreading caudally</li> </ul>
Excellent	<ul style="list-style-type: none"> <li>Only caudal spread of the CM</li> </ul>

Abbreviation: CM, contrast medium.

Accuracy	
Excellent	<ul style="list-style-type: none"> <li>Intraconal needle position</li> <li>Intraconal spread of CM</li> <li>CM reached the orbital fissure</li> <li>Approximate contact area of the injectate around the optic nerve <math>\geq 270^\circ</math></li> </ul>
Moderate	<ul style="list-style-type: none"> <li>Three out of 4 criteria of an excellent accuracy fulfilled</li> </ul>
Poor	<ul style="list-style-type: none"> <li><math>\leq 2</math> out of 4 criteria of an excellent accuracy fulfilled</li> </ul>
Safety	
Excellent	<ul style="list-style-type: none"> <li>Distance of the needle tip to the optic nerve <math>\geq 5</math> mm</li> <li>No intraocular, intravascular, intrathecal, or intraneural puncture</li> </ul>
Moderate	<ul style="list-style-type: none"> <li>Distance of the needle tip to the optic nerve <math>&lt; 5</math> mm</li> <li>No intraocular, intravascular, intrathecal, or intraneural puncture</li> </ul>
Poor	<ul style="list-style-type: none"> <li>Intraocular, intravascular, intrathecal, or intraneural puncture, irrespective of the distance of the needle tip to the optic nerve</li> </ul>

Abbreviation: CM, contrast medium.

Between group comparisons of the average depths of intraconal and extraconal needles were performed using a Student *t*-test. Comparison between injection techniques (blind or US-guided) regarding needle position (intraconal: yes or no; intraocular: yes or no), location of CM (intraconal: yes or no; intraocular: yes or no; intravascular: yes or no; intrathecal: yes or no; intraneural: yes or no), accuracy (excellent vs. good or poor), and safety (excellent vs. good or poor) were assessed with cross-tabulations and Fisher's exact test (FET). Comparison between blind and US-guided injection regarding the distance from the needle tip to the optic nerve (needle tip to nerve in mm), needle depth (skin surface to needle tip in mm), and distance of leading edge of CM to the orbital fissure (distance in mm to the crista pterygoideus) were performed with the Student's

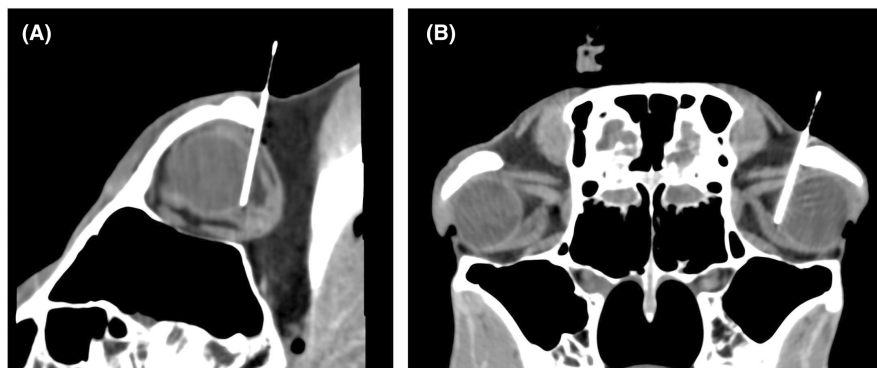
*t*-test or Mann–Whitney U-test, depending on the distribution of measurements. Comparisons between the ultrasound visualization score and accuracy (excellent vs. good or poor) and safety (excellent vs. good or poor) were assessed using cross-tabulations and FET. Descriptive statistics are presented either as mean and standard deviation (SD) or as proportions (%). For all statistical analyses, *p* values  $< .05$  were considered statistically significant.

### 3 | RESULTS

Injection of the retrobulbar space was performed 88 times in total. Orbits were injected either with the blind or the US-guided injection technique, 44 of each, equally divided

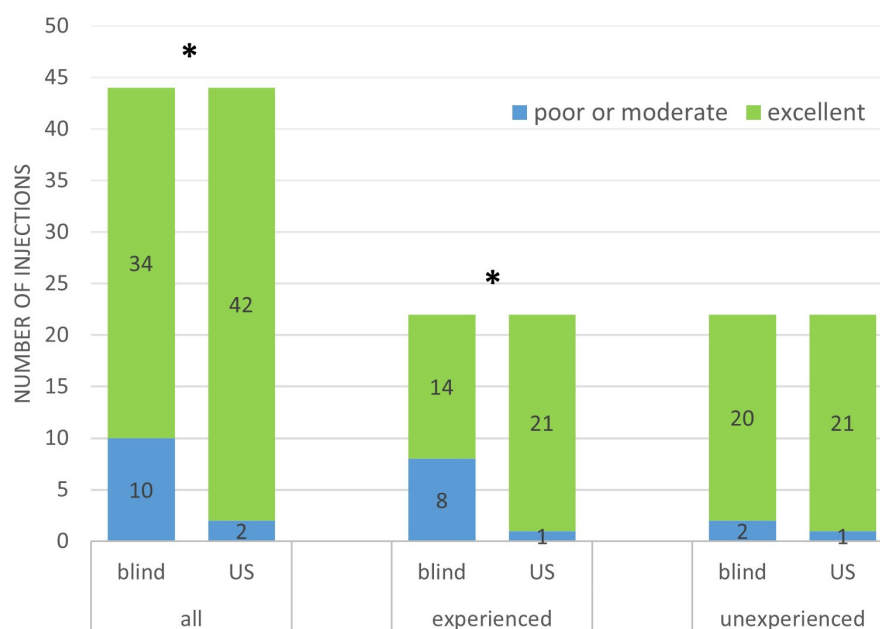
**TABLE 1** Criteria for classifying the ultrasound visualization and spread of the injectate during the ultrasound-guided technique for the dorsal retrobulbar nerve block in horses, modified after Morath et al.<sup>12</sup>

**TABLE 2** Criteria for classifying the dorsal retrobulbar nerve block based on computed tomographic images in horses, modified after Morath et al.<sup>12</sup> and Shilo-Benjamini et al.<sup>17</sup>



**FIGURE 3** Sagittal (A) and transversal (B) computed tomography image showing needle placement after performance of the dorsal retrobulbar nerve block in a horse cadaver with the blind injection technique. The needle passes through the eye, corresponding to poor injection safety, before reaching the desired position in the craniocentral part of the retrobulbar muscle cone.

**FIGURE 4** Comparison of the safety of the blind (blind) and ultrasound-guided (US) injection technique for the dorsal retrobulbar nerve block in horses: all, all injections ( $n = 88$ ); experienced, injections performed by the experienced operator ( $n = 44$ ); unexperienced, injection performed by the unexperienced operator ( $n = 44$ ). \* Statistically significant difference,  $p < .05$ .



between an experienced and unexperienced operator. All heads were processed within 72 h (range 12–72 h, mean 42.5 h).

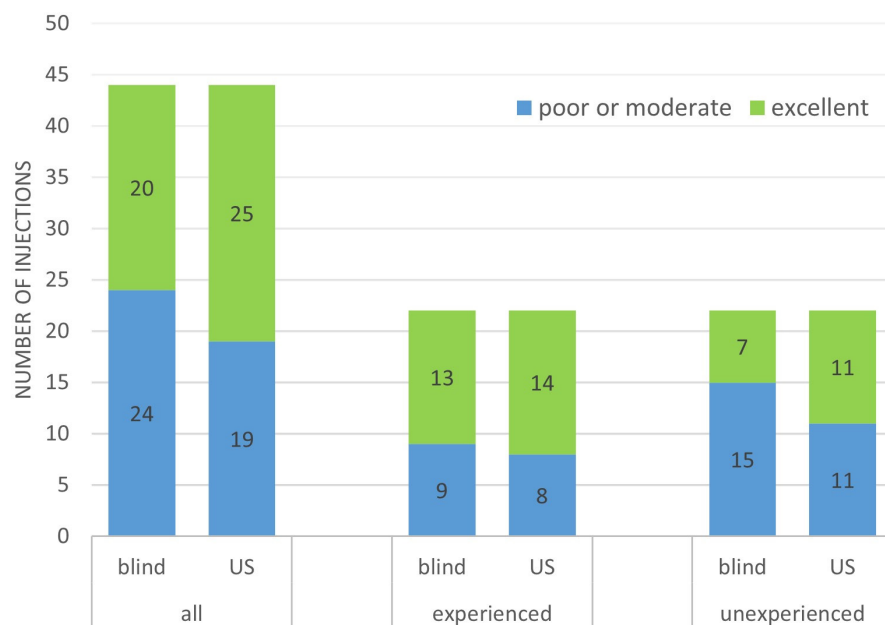
Major complications were rarely observed. Ocular penetration was observed in two cases ( $n = 2/44$ ) of the blindly injected orbits, one by the experienced and one by the unexperienced operator, and in none of the orbits injected under US guidance ( $n = 0/44$ ). In the case of the unexperienced operator, the injection of the CM was intraocular. The experienced operator passed the needle through the eye, before reaching the desired position in the retrobulbar muscle cone (Figure 3). In this case, CM spread was intraconally. On both occasions, the operators were not aware that ocular penetration occurred. No intrathecal, intraneural, or intravascular injections were seen.

Safety was significantly improved with US guidance ( $p = .026$ ). When the experienced and unexperienced operators were evaluated separately, the safety improvement

was statistically significant only for the experienced operator (Figure 4).

There was no statistically significant difference between the injection techniques regarding needle position, location of CM, or accuracy of the injection. Extraconal needle placement occurred in three blindly injected orbits and two orbits injected under US guidance. Excellent accuracy was achieved more often with the US-guided technique ( $n = 11/22$ ) than with the blind technique ( $n = 7/22$ ) when performed by the unexperienced operator (Figure 5). Likewise, the CM reached the orbital fissure more often with the US-guided technique ( $n = 12/22$ ) than with the blind technique ( $n = 7/22$ ) when performed by the unexperienced operator (Table 3), but these differences were not statistically significant.

The distance of the needle tip to the optic nerve and the needle depth were normally distributed. The distance from the needle tip to the optic nerve was significantly



**FIGURE 5** Comparison of the accuracy of the blind (blind) and ultrasound-guided (US) injection technique for the dorsal retrobulbar nerve block in horses: all, all injections ( $n = 88$ ); experienced, injections performed by the experienced operator ( $n = 44$ ); unexperienced, injection performed by the unexperienced operator ( $n = 44$ ).

**TABLE 3** Descriptive statistics of the blind injection technique (blind) and ultrasound-guided injection technique (US) for the dorsal retrobulbar nerve block in horses.

	Number of injections where the CM reached orbital fissure <sup>a</sup>	Distance of the CM to the orbital fissure (mm) <sup>b</sup>	Distance from the needle tip to the ON (mm) <sup>b</sup>	Needle depth (mm) <sup>b</sup>	Total <sup>a</sup>
Blind total	20	$8.3 \pm 12.2$	$10.1 \pm 5.9$	$49.6 \pm 6.9$	44
Blind OP1	13	$5.1 \pm 8.7$	$7.6 \pm 5.7$	$51.9 \pm 5.8$	22
Blind OP2	7	$11.6 \pm 14.5$	$12.6 \pm 5.1$	$47.2 \pm 7.3$	22
US total	26	$8.8 \pm 13.8$	$13.1 \pm 5.1$	$43.5 \pm 8.2$	44
US OP1	14	$7.2 \pm 12.0$	$14.8 \pm 5.2$	$41.0 \pm 9.7$	22
US OP2	12	$10.4 \pm 15.6$	$11.5 \pm 4.5$	$46.1 \pm 5.5$	22
Total	46				88

Note: Data are expressed as  $n$  - values<sup>a</sup> or as mean  $\pm$  standard deviation<sup>b</sup>.

Abbreviations: CM, contrast medium; ON, optic nerve; OP1, experienced operator; OP2, unexperienced operator.

shorter ( $13.1 \pm 5.1$  mm), and needle depth was significantly greater ( $49.6 \pm 6.9$  mm) in the blindly injected orbits compared to orbits injected under US guidance ( $10.1 \pm 5.9$  mm,  $p = .012$  and  $43.5 \pm 8.2$  mm,  $p < .001$ , respectively). This difference was particularly emphasized in the case of the experienced operator (Table 3). The distance of the CM to the orbital fissure was not normally distributed. The distance of the leading edge of CM to the orbital fissure was not significantly different between the blindly injected orbits and the orbits injected under US guidance (Table 3).

The needle depth of intra- vs. extraconal needle placement was not significantly different. Out of the five extraconal injections, two were performed by the experienced operator and three by the unexperienced operator. In the extraconal injections performed under US guidance ( $n = 2$ ), the spread of the CM was classified as excellent and no anterior spread of CM was noticed in the

CT images. In the three blindly performed extraconal injections, two showed no anterior spread of the CM and one showed anterior spread of the CM in the CT images. Anterior spread of the CM observed by CT-imaging was seen in the majority of orbits ( $n = 66/88$ , 75%). Scoring of the ultrasound visualization of the orbital structures and needle placement was poor in two cases, good in 26 cases, and excellent in 16 cases. Ultrasound visualization did not correlate significantly with injection accuracy, injection safety, or with anterior spread of CM as observed during CT-imaging.

## 4 | DISCUSSION

This study shows that US-guided retrobulbar nerve blocks can provide superior safety of the injection compared to

blindly performed injections. US guidance can prevent devastating complications that would lead to the loss of vision or even loss of the eye. This would be catastrophic in all globe-sparing surgeries and could cause considerable complications in enucleations due to endophthalmitis or intraocular tumorous disease. Inadvertent ocular penetration occurred in two cases in our study, both in the group of the blindly injected orbits ( $n = 2/44$ , 4.5%). Ocular penetration is a very rare complication, reported in only 0.075% of blindly performed retrobulbar nerve blocks in humans.<sup>20</sup> In veterinary studies, ocular penetration also occurred infrequently, but, as in our study, was not seen with US-guided injections in dogs,<sup>21</sup> horses,<sup>14,16</sup> dromedary camels,<sup>22</sup> or donkeys,<sup>23</sup> even with unexperienced operators. One cadaveric study in horses showed no intraocular injections with the blind technique for the peribulbar nerve block,<sup>15</sup> yet also none of the blindly performed blocks were injected in their intended location. The low number of complications in our study could be, in part, the result of a lack of movement of the cadaveric specimens as compared to live animals. The ability to visualize important structures in real time is a great advantage of the US-guided technique, especially in potentially moving animals.

Our data show significantly improved safety of the retrobulbar injections with US guidance compared to the blind injection technique for the experienced operator without losses in accuracy. When performed by the unexperienced operator, both injection techniques resulted in excellent safety in most cases (20/22 and 21/22 for the blind and US-guided injection technique, respectively). The unexperienced operator performed more injections with excellent accuracy with US guidance ( $n = 11/22$ ) as compared to blindly injected orbits ( $n = 7/22$ ) yet this difference was not statistically significant. Safety and accuracy need to be evaluated in combination to rate the quality of the injection. An injection can be placed far from the intended location resulting in excellent safety, but the desired accuracy will not be achieved.

There was no significant difference in injection safety or accuracy when comparing the experienced and unexperienced operators. It could be argued that the unexperienced operator cannot be regarded as such after performing multiple retrobulbar injections. It cannot be told how many injections are necessary to gain a good experience level and largely depends on the skilfulness of the operator. To better estimate the influence of the experience level on the outcome of the injections, multiple operators of each experience level would need to be acquired for future studies, to assure constant levels of experience and prevent a training effect.

The study by Hermans et al.<sup>16</sup> examining the training effect of US guidance in DRNB placement found no

significant difference, yet a trend toward significant improvement in accuracy for US guidance compared to the blindly performed injection. A similar training effect could not be observed in our study when comparing the accuracy of the first and second half of the injections of each operator (data not shown). One reason for this could be that the blind and US-guided injections were randomly assigned, so the operators used the US-guided technique from the very beginning of the study. They were able to see how the needle needs to be inserted to reach the retrobulbar muscle cone when performing the US-guided technique and could then extrapolate this knowledge to the blindly injected orbits. Therefore, the two studies are not comparable with regard to the training effect. Interestingly, the unexperienced operator showed poorer performance during the second half of our study. The reason for this remains unknown.

Intrathecal injections can cause brainstem anesthesia.<sup>9</sup> Considering surgeries in the equine patient without immediate access to positive pressure ventilation and standing in stocks, an intrathecal injection would result in a life-threatening situation for the patient and an extremely dangerous situation for the animal handlers. There are no reports of this complication in horses. Brainstem anesthesia was suspected following a retrobulbar block in a cat under general anesthesia.<sup>8</sup> As the blood vessels and meningeal sheaths are collapsed in cadaver heads, they were less likely to get punctured in the cadaver specimens compared to living animals. Also, due to their collapsed state, they were not clearly identifiable on the CT images. It must be assumed, that if the optic nerve sheath would have been punctured in the cadaveric specimens in our study, there would be a high resistance during the injection of the CM, which was not observed in any of the cases. Needle position before injection of contrast medium would have to indicate optic nerve puncture and the CM would follow the subarachnoid space toward the brain stem. None of the cases in this study showed optic nerve puncture or intracranial extension of CM on CT images. Therefore, optic nerve sheath puncture is considered unlikely.

In our study, we used a retrobulbar injection technique similar to that described by Morath et al.<sup>14</sup> Therein, the needle is inserted caudally to the supraorbital rim, while image acquisition is obtained with a curved array ultrasound transducer placed on the closed upper eyelid. In the study by Morath et al.,<sup>14</sup> the anatomical structures of the retrobulbar space (the retrobulbar muscle cone, the optic nerve, and the bony shadow of the orbit) and needle could all be visualized during ultrasound imaging in all but one case. In 29.4% of the injections, the needle and optic nerve could be imaged simultaneously on ultrasound, corresponding to excellent visualization. In our study, we used

a linear ultrasound transducer. Excellent visualization was achieved in 36.4% of cases. One of the main advantages of using US guidance for injections is the avoidance of vital structures. One could argue the technique described by Morath et al.<sup>14</sup> does not completely meet all the criteria to be classified as a safe US-guided injection technique,<sup>24</sup> as the relevant structures cannot all be visualized simultaneously in real time during the procedure. This applies to most of the cases in both our study and the study by Morath et al.<sup>14</sup> In another study,<sup>15</sup> an in plane ultrasonographic approach was proposed for a peribulbar nerve block with a phased array ultrasound transducer placed in the supraorbital fossa. Although the authors did not apply an ultrasound visualization score, in two out of ten cases the operators described difficulties in identifying the ultrasound landmarks. Therefore, there is still room for refinement of US-guided retro- and peribulbar injection techniques to further improve safety and efficiency.

Observation of the spread of the CM with ultrasound visualization was possible only during the injection of the first approximately 4 ml of the injectate. During the injection of the remaining 8 ml, the ultrasound image did not change in most instances which could lead to a false interpretation of the spread of the injectate during ultrasound imaging. There was no significant correlation between ultrasound visualization and injection accuracy, but this was probably in part due to the study design, which did not provide for repositioning of the needle in the event of unsatisfactory contrast medium spread during ultrasound imaging. In a real-life setting, the clinician would reposition the needle to provide adequate local anesthetic spread. On the contrary, the extraconal injections performed under US guidance in our study ( $n = 2$ ) showed excellent CM spread during ultrasound visualization, and no anterior spread of CM was noticed in the CT images.

In our study, we observed that the insertion of the needle into the extraocular muscle cone during the blind injection technique provided a barely noticeable movement of the globe and, in most instances, no movement of the globe was noticed ( $n = 37/44$ ). The previously described “popping” sensation was inconsistently observed ( $n = 19/44$ ). This difficulty was not reported in previous clinical<sup>6,25</sup> or cadaver<sup>16</sup> studies in horses. In frozen specimens, the effects of the freeze–thaw process on soft tissues can potentially change their biomechanical characteristics. It has been reported that a significant alteration in mechanical and morphological properties of the muscles due to the freeze–thaw procedure occurs.<sup>26–28</sup> This does not apply to the specimens in our study as all cadaver heads were fresh and the maximum time between death and performance of the retrobulbar block comprised 72 h with a mean time of 42.5 h. This limitation also occurred in specimens processed within the first 24 h after death. In the study by Hermans et al.,<sup>16</sup> frozen-thawed

specimens were used alongside fresh specimens but the authors of that study did not report similar difficulties. One reason for this difference could be attributed to the usage of a larger gauge needle (20 G) compared to our study (22 G). In the clinical setting, where the authors of this study use the same quincke type point spinal needle for the DRNB as in the presented cadaver study, we do not encounter these difficulties. This is in concordance with the study by Yang et al.<sup>6</sup> in live horses, where a 22 G, quincke point type spinal needle was used as well. On the contrary, Yang et al.<sup>6</sup> pointed out that although they received tactile feedback and/or observed globe rotation during all the retrobulbar injections, one of the retrobulbar injections in their study did not produce reliable anesthesia, which made the authors assume that the injection was placed extraconally. The lack of tactile or visual feedback during most of the blind injections in our study could have biased the outcome of the blindly injected orbits, yet only three of the 44 blindly injected orbits showed an extraconal needle position. Interestingly, in the two cases of ocular penetration, the operators were not aware of this event. During the injection, the experienced operator felt a popping sensation without globe rotation, whereas the unexperienced operator did not feel a popping sensation and did not observe globe rotation. In future studies, the distance from the needle to the globe should be included in the evaluation of injection safety.

A recent study observed chemosis as a common complication following DRNB in horses injected with 10 ml of 2% lidocaine.<sup>6</sup> The authors proposed local tissue reaction to the injectate or slow anterior diffusion of the injectate as observed during a pilot cadaver study<sup>6</sup> as possible reasons for this complication. Chemosis was observed starting 4 h post-injection with the resolution of swelling at 72 h in all but one horse. We observed anterior spread of CM in 66/88 (75%) of injected orbits on CT images, yet this would most likely result in immediate chemosis. Allergic reactions following local anesthetic injections are most likely attributable to preservatives (methylparaben) contained in the solution.<sup>29</sup>

Commonly used local anesthetic agents for retrobulbar injections are lidocaine and mepivacaine. Because of the large volumes of lidocaine required to produce toxicity in an adult horse, toxicity is unlikely to happen under normal circumstances.<sup>30</sup> In cases of inflammatory orbital disease (e.g., retrobulbar cellulitis or abscessation), a decreased efficacy of the local anesthetic agent could be expected, most likely due to the reduced tissue pH.<sup>9</sup> Although clinical evidence for this phenomenon is sparse, insufficient analgesia and potentially defensive movements should be considered as a consequence in patients with this type of disease. Multimodal pain management and potentially conversion to general anesthesia should be considered and planned for.<sup>31</sup> The authors



of this study used a volume of 12 ml of CM because this volume is commonly recommended for DRNBs<sup>4,5,32,33</sup> and had an improved outcome in the study by Morath et al.,<sup>14</sup> where 28/43 injections with the use of 12 ml of injectate reached the orbital fissure compared to 23/43 of the injections where 8 ml of injectate was used, although this difference was not statistically significant. The injection volume potentially has an effect on the degree of chemosis and rise in intraocular pressure.<sup>6</sup> To reduce these side effects, injection volume could be adjusted to the orbital dimensions like in dogs.<sup>34,35</sup> To the authors' knowledge, orbital dimensions and their relationship to bodyweight, breed, or age have not been examined in horses. Moreover, local anesthetics vary in their potency. This is largely the result of differences in lipid solubility and could influence the needed injection volume. Placement of the needle further away from the eyeball and therefore closer to the orbital fissure could decrease the required injection volume, yet the injection technique is potentially more difficult to perform due to the smaller diameter of the retrobulbar muscle cone and increased risk of intrameningeal or intraneural injection. More research evaluating the minimal effective dose and different local anesthetics for retrobulbar anesthesia is necessary.

Complications associated with surgery under general anesthesia include systemic hypotension, movement of the horse during the procedure, and difficult or prolonged recoveries. Horses anesthetized for ocular surgery experience these complications with significantly greater frequency than horses anesthetized for other types of surgery.<sup>36</sup> Performing surgeries with the horse sedated and standing eliminates the risks and expense of general anesthesia. In the standing equine patient, it is crucial to provide reliable local analgesia for the safety of the horse, the veterinary surgeon, and the animal handlers. Preoperative retrobulbar anesthesia impedes all nociception during surgery, which may prevent the windup effect causing increased pain sensation after surgery<sup>37-39</sup> and therefore reduce the need for NSAIDs. Some horses may have comorbidities that represent a contraindication for the use of NSAIDs. In dogs undergoing enucleation, a decreased need for postoperative analgesics after retrobulbar anesthesia was demonstrated<sup>40</sup> and a US-guided approach was shown to be more effective in decreasing intraoperative opioid analgesia than a blind approach.<sup>21</sup>

Limitations of this study include the use of cadaver specimens only. The specimens had no orbital injuries, so the effects of orbital abnormalities in living horses remain unknown. Anesthetic solutions are hydrophilic yet the CMs are most often lipophilic. To address this problem, a CM of superior hydrophilic properties compared to other

CMs was chosen. In addition, by storage at 37°C, the CM becomes more hydrophilic and less viscous and is, therefore, more similar in its properties when compared to an anesthetic solution. However, the anesthetic solution may have a different pattern of distribution in the living organism, especially when considering the body temperature and cardiovascular effects of a living animal. Moreover, the proposed safety and accuracy in the present study are defined on objective scores from CT images, which have not been correlated with analgesic effectiveness in living animals. Further clinical research should be performed to determine the feasibility of the US-guided approach in living, sedated animals including the pattern of distribution of local anesthetic agents, the onset and duration of the nerve analgesia, and the potential complications.

In conclusion, ultrasonographic guidance reduces the risk of catastrophic complications of retrobulbar injections compared to blindly injected orbits. To improve the safety of the injection, we recommend using the US-guided injection technique for the retrobulbar nerve block. Future studies should focus on refining the ultrasonographic technique, the use of different local anesthetics, and evaluating the minimal effective dosage of the local anesthetics.

## ACKNOWLEDGMENTS

The authors would like to thank Ronny Weiland and Marco Heinhold for their technical assistance during the study. This study was supported by a Research Grant of the European College of Veterinary Ophthalmologists (ECVO).

## ORCID

Katharina Thieme  <https://orcid.org/0000-0002-4585-6916>

## REFERENCES

- Grubb T, Lobprise H. Local and regional anaesthesia in dogs and cats: overview of concepts and drugs (part 1). *Vet Med Sci*. 2020;6(2):209-217.
- Romano M, Portela DA, Breggi G, Otero PE. Stress-related biomarkers in dogs administered regional anaesthesia or fentanyl for analgesia during stifle surgery. *Vet Anaesth Analg*. 2016;43(1):44-54.
- Shilo-Benjamini Y. A review of ophthalmic local and regional anesthesia in dogs and cats. *Vet Anaesth Analg*. 2019;46(1):14-27.
- Labelle AL, Clark-Price SC. Anesthesia for ophthalmic procedures in the standing horse. *Vet Clin North Am Equine Pract*. 2013;29(1):179-191.
- Oel C, Gerhards H, Gehlen H. Effect of retrobulbar nerve block on heart rate variability during enucleation in horses under general anesthesia. *Vet Ophthalmol*. 2014;17(3):170-174.
- Yang VY, Eaton JS, Harmelink K, et al. Retrobulbar lidocaine injection via the supraorbital fossa is safe in adult horses but produces regionally variable periorbital anaesthesia. *Equine Vet J*. 2022;54:807-819.

7. Robertson SA. Standing sedation and pain management for ophthalmic patients. *Vet Clin North Am Equine Pract.* 2004;20(2):485-497.
8. Oliver JA, Bradbrook CA. Suspected brainstem anesthesia following retrobulbar block in a cat. *Vet Ophthalmol.* 2013;16(3):225-228.
9. Grimm K, Lamont L, Tranquilli W, Greene S, Robertson S. *Lumb and Jones Veterinary Anesthesia and Analgesia.* John Wiley & Sons, Inc; 2015.
10. Gayer S, Palte HD. Ultrasound-guided ophthalmic regional anesthesia. *Curr Opin Anaesthesiol.* 2016;29(6):655-661.
11. Lewis SR, Price A, Walker KJ, McGrattan K, Smith AF. Ultrasound guidance for upper and lower limb blocks. *Cochrane Database Syst Rev.* 2015;2015(9):CD006459.
12. Walker KJ, McGrattan K, Aas-Eng K, Smith AF. Ultrasound guidance for peripheral nerve blockade. *Cochrane Database Syst Rev.* 2009;(4):CD006459.
13. Wagatsuma JT, Deschke M, Floriano BP, et al. Comparison of anesthetic efficacy and adverse effects associated with peribulbar injection of ropivacaine performed with and without ultrasound guidance in dogs. *Am J Vet Res.* 2014;75(12):1040-1048.
14. Morath U, Luyet C, Spadavecchia C, Stoffel MH, Hatch GM. Ultrasound-guided retrobulbar nerve block in horses: a cadaveric study. *Vet Anaesth Analg.* 2013;40(2):205-211.
15. Leigh H, Gozalo-Marcilla M, Esteve V, Bautista AJG, Gimenez TM, Viscasillas J. Description of a novel ultrasound guided peribulbar block in horses: a cadaveric study. *J Vet Sci.* 2021;22(2):e22.
16. Hermans H, Lloyd-Edwards RA, Ferrão-van Sommeren AJH, et al. Comparing blind and ultrasound-guided retrobulbar nerve blocks in equine cadavers: the training effect. *Animals.* 2022;12(2):154.
17. Najman IE, Ferreira JZ, Abimussi CJ, et al. Ultrasound-assisted periconal ocular blockade in rabbits. *Vet Anaesth Analg.* 2015;42(4):433-441.
18. Stoppini R, Gilger BC. Equine ocular examination basic techniques. In: Gilger BC, ed. *Equine Ophthalmology.* 3rd ed. John Wiley & Sons; 2016:1-39.
19. Shilo-Benjamini Y, Pascoe PJ, Maggs DJ, Kass PH, Wisner ER. Retrobulbar and peribulbar regional techniques in cats: a preliminary study in cadavers. *Vet Anaesth Analg.* 2013;40(6):623-631.
20. Wadood AC, Dhillon B, Singh J. Inadvertent ocular perforation and intravitreal injection of an anesthetic agent during retrobulbar injection. *J Cataract Refract Surg.* 2002;28(3):562-565.
21. Briley J, Chiavaccini L, Washington D, Westermeyer H, Posner L. Comparison of a blind and an ultrasound-guided technique for retrobulbar anesthesia in dogs undergoing unilateral subconjunctival enucleation. *Vet Anaesth Analg.* 2021;48(6):S984-S985.
22. Badawy AM, Eshra EA. Development of an ultrasound-guided technique for retrobulbar nerve block in dromedary camels: a cadaveric study. *Vet Anaesth Analg.* 2018;45(2):175-182.
23. Hagag U, ElNahas A. Ultrasound-guided retrobulbar nerve block in donkey cadavers. *Vet Anaesth Analg.* 2022;49(2):197-202.
24. Johnson JP, Vinardell T, David F. Ultrasound-guided injections of the equine head and neck: review and expert opinion. *J Equine Sci.* 2021;32(4):103-115.
25. Tóth J, Hollerrieder J. Experiences with the local retrobulbar anesthesia in ophthalmologic surgery of the standing horse. *Pferdeheilkunde.* 2013;29(1):21-26.
26. Gottsauner-Wolf F, Grabowski JJ, Chao EYS, An K-N. Effects of freeze/thaw conditioning on the tensile properties and failure mode of bone-muscle-bone units: a biomechanical and histological study in dogs. *J Orthop Res.* 1995;13(1):90-95.
27. Jalal N, Zidi M. Effect of cryopreservation at  $-80^{\circ}\text{C}$  on viscohyperelastic properties of skeletal muscle tissue. *J Mech Behav Biomed Mater.* 2018;77:572-577.
28. Maiden NR, Byard RW. Unpredictable tensile strength biomechanics may limit thawed cadaver use for simulant research. *Aust J Forensic Sci.* 2016;48(1):54-58.
29. Becker DE, Reed KL. Local anesthetics: review of pharmacological considerations. *Anesth Prog.* 2012;59(2):90-103.
30. Meyer GA, Lin HC, Hanson RR, Hayes TL. Effects of intravenous lidocaine overdose on cardiac electrical activity and blood pressure in the horse. *Equine Vet J.* 2001;33(5):434-437.
31. Löscher W, Richter A. *Lehrbuch der Pharmakologie und Toxikologie für die Veterinärmedizin.* Georg Thieme Verlag; 2016.
32. Gilger BC, Davidson MG. How to prepare for ocular surgery in the standing horse. Presented at: Annual Convention of the AAEP; Orlando. 2002.
33. Eberspächer-Schweda E. Sedierung und Lokalanästhesie bei Eingriffen am Kopf des Pferdes. *Pferdespiegel.* 2017;20(2):50-59.
34. Klaumann PR, Moreno JCD, Montiani-Ferreira F. A morphometric study of the canine skull and periorbita and its implications for regional ocular anesthesia. *Vet Ophthalmol.* 2018;21(1):19-26.
35. Greco A, Costanza D, Senatore A, et al. A computed tomography-based method for the assessment of canine retrobulbar cone volume for ophthalmic anaesthesia. *Vet Anaesth Analg.* 2021;48(5):759-766.
36. Parviainen A, Trim C. Complications associated with anaesthesia for ocular surgery: a retrospective study 1989–1996. *Equine Vet J.* 2000;32(6):555-559.
37. Ploog CL, Swinger RL, Spade J, Quandt KM, Mitchell MA. Use of lidocaine-bupivacaine-infused absorbable gelatin hemostatic sponges versus lidocaine-bupivacaine retrobulbar injections for postoperative analgesia following eye enucleation in dogs. *J Am Vet Med Assoc.* 2014;244(1):57-62.
38. Chow DW, Wong MY, Westermeyer HD. Comparison of two bupivacaine delivery methods to control postoperative pain after enucleation in dogs. *Vet Ophthalmol.* 2015;18(5):422-428.
39. Zibura AE, Posner LP, Ru H, Westermeyer HD. A preoperative bupivacaine retrobulbar block offers superior antinociception compared with an intraoperative splash block in dogs undergoing enucleation. *Vet Ophthalmol.* 2020;23(2):225-233.
40. Myrna KE, Bentley E, Smith LJ. Effectiveness of injection of local anesthetic into the retrobulbar space for postoperative analgesia following eye enucleation in dogs. *J Am Vet Med Assoc.* 2010;237(2):174-177.

**How to cite this article:** Thieme K, Mesquita L, Lieberth S, Dancker C, Doherr MG, Eule JC. Safety and accuracy of blind vs. ultrasound-guided dorsal retrobulbar nerve blocks in horses—A cadaveric study. *Vet Ophthalmol.* 2022;00:1-10. doi:[10.1111/vop.13053](https://doi.org/10.1111/vop.13053)